

From:

**MRI Bioeffects, Safety, and Patient Management**

Frank G. Shellock, Ph.D. and John V. Crues, III, M.D. - Editors

© 2014, ISBN-13 978-0-9891632-0-0

Biomedical Research Publishing Group

Single use ONLY. Do not copy or distribute. Copyright 2014

## Chapter 16 MRI Issues for Implants and Devices

FRANK G. SHELLOCK, PH.D.

Adjunct Clinical Professor of Radiology and Medicine  
Keck School of Medicine, University of Southern California

Adjunct Professor of Clinical Physical Therapy  
Division of Biokinesiology and Physical Therapy  
School of Dentistry, University of Southern California

Director for MRI Studies of Biomimetic MicroElectronic Systems  
National Science Foundation, Engineering Research Center  
University of Southern California

Institute for Magnetic Resonance Safety, Education, and Research  
President, Shellock R & D Services, Inc.  
Los Angeles, CA

### INTRODUCTION

An important aspect of protecting patients from magnetic resonance imaging (MRI)-related accidents and injuries involves an understanding of the risks associated with the implants, devices, and other objects (e.g., metallic foreign bodies) that may cause problems in this setting. This requires constant attention and diligence to obtain information and documentation about these items as part of the screening procedure in order to provide the safest MRI environment possible.

The standard of care for managing a patient referred for an MRI procedure with an implant or device is to positively identify the type of item that is present and then to determine the relative safety of scanning the patient. This is best accomplished by either referring to the MRI-specific labeling for the implant or device or by reviewing the *ex vivo* testing that was performed on the object and published in the peer-reviewed literature.

This chapter will discuss the important MRI-related issues for implants and devices and present information for a variety of common and not so common medical products. Notably, an annually revised textbook provides vital information for thousands of implants and de-

## 376 MRI Issues for Implants and Devices

vices and there is a website, [www.MRIsafety.com](http://www.MRIsafety.com), with pertinent content that is updated on a regular basis (1, 2). Therefore, the reader is directed to these resources when specific information is needed.

### MRI ISSUES FOR IMPLANTS AND DEVICES

MRI may be contraindicated for a given patient primarily because of risks associated with movement or dislodgment of a ferromagnetic implant or device (1-4). There are other possible hazards and problems related to the presence of a metallic object or one made from conductive materials that include excessive heating, induction of currents (i.e., in materials that are conductors), changes in the operational aspects of the device, damage to the function of the device, the difficulty in interpreting MR images due to signal loss and/or distortion, and the misinterpretation of an imaging artifact as an abnormality (1-4). In consideration of the above, *ex vivo* testing is performed to assess the various MRI issues for implants and devices in order to properly characterize the possible risks (1-32).

#### Magnetic Field Interactions

With regard to magnetic field interactions and MRI, translational attraction and/or torque may cause movement or dislodgment of a ferromagnetic implant, resulting in an uncomfortable sensation for the patient, an injury, or even a fatality (1, 2). Therefore, both translational attraction and torque are important to evaluate for implants and devices before patients with metallic objects are allowed to undergo MRI.

The effect of translational attraction acting on an implanted ferromagnetic object is predominantly responsible for a hazard that may occur in the immediate area of the MR system. That is, as one moves closer to the scanner or as the patient is moved into the bore for the MRI examination. The predominant effect of torque (or rotational alignment to the magnetic field) as it acts on a ferromagnetic object occurs in the center of the MR system, where the magnetic field is most homogenous. Notably, torque will greatly influence implants and devices that have an elongated shape. Obviously, both translational attraction and torque combine to impact a ferromagnetic implant or device as the patient with the object moves towards the MR system and then into the center of the bore of the scanner (1, 2).

Various factors influence the risk of performing MRI in a patient with a metallic object including the strength of the static magnetic field, the level of the spatial gradient magnetic field, the magnetic susceptibility of the object, the mass of the object, the geometry of the object, the location and orientation of the object *in situ*, the presence of retentive mechanisms (i.e., fibrotic tissue, sutures, etc.), and the length of time the object has been implanted. These factors should be carefully considered before subjecting a patient with a ferromagnetic object to an MRI examination. This is particularly important if the object is located in a potentially dangerous area of the body such as a vital neural, vascular, or soft tissue structure where movement or dislodgment could injure the patient.

With respect to the potential risks for a ferromagnetic implant, in addition to the findings for translational attraction and torque, the “intended *in vivo* use” of the implant or device must be considered as well as the mechanisms that may provide retention of the object once it is implanted (e.g., implants or devices held in place by sutures, granulation or ingrowth

**MRI Bioeffects, Safety, and Patient Management 377**

of tissue, fixation devices, or by other means). Accordingly, sufficient counterforces may exist to retain even a ferromagnetic implant in place, *in situ*.

Numerous studies have assessed magnetic field interactions for implants and other items by measuring translational attraction and torque associated with the static magnetic fields of MR systems (1, 2). These investigations demonstrated that MRI can be performed safely in patients with metallic objects that are nonferromagnetic or “weakly” ferromagnetic (i.e., only minimally attracted by the magnetic field), such that the magnetic field interactions are insufficient to move or dislodge them, *in situ*.

Additionally, patients with certain implants or devices that have relatively strong ferromagnetic qualities may be safely scanned using MRI because the objects are held in place by retentive forces that prevent them from being moved or dislodged with reference to the “intended *in vivo* use” of the object. For example, there is an interference screw (i.e., the Perfix Interference Screw) used for reconstruction of the anterior cruciate ligament that is highly ferromagnetic. However, once this implant is implanted (i.e., screwed into the patient’s bone), this prevents it from being moved, even if the patient is exposed to a 1.5-Tesla MR system. Other implants that exhibit substantial ferromagnetic qualities may likewise be safe for patients undergoing MRI under highly specific conditions as a result of the presence of counterforces that prevent movement of these objects.

In general, each implant or other item should be evaluated using *ex vivo* techniques to test translational attraction and torque before allowing a patient with the object to undergo MRI (1, 2). By following this guideline, the magnetic susceptibility for an object may be considered so that a competent decision can be made concerning possible risks associated with subjecting the patient to MRI. Because movement or dislodgment of an implanted metallic object is the main mechanism responsible for an injury, this aspect of testing is considered to be of utmost importance and should involve the use of an MR system operating at an appropriate static magnetic field strength (i.e., if the intent is to scan the patient with the implant at 3-Tesla, the implant must be tested for magnetic field interactions at that field strength).

In certain cases, there is a possibility of changing the operational or functional aspects of the implant or device as a result of exposure to the powerful static magnetic field of the MR system. For an implant that has a component that is magnetic (e.g., cochlear implants, programmable cerebral spinal fluid shunt valves, etc.), it is possible to disrupt the functional aspects of the device or to demagnetize the magnet, rendering it unacceptable for its intended use (1, 2). Therefore, this important aspect must be evaluated using comprehensive testing techniques to verify that specific MRI conditions will not alter the function of the device.

MR systems with very low (0.2-Tesla or less) or very high (9.4-Tesla) static magnetic fields are currently used for clinical and research applications. Considering that most metallic objects evaluated for magnetic field interactions were assessed at 1.5- or 3-Tesla, an appropriate variance or modification of the information provided regarding the safety of performing an MRI procedure in a patient with a metallic object may exist when a scanner with a lower or higher static magnetic field strength was used for testing. Therefore, it may be acceptable to adjust safety recommendations depending on the static magnetic field strength and other aspects of a given scanner. Obviously, performing an MRI procedure

### 378 MRI Issues for Implants and Devices

using a 0.2-Tesla MR system has different risk implications for a patient with a ferromagnetic object compared with using a 9.4-Tesla scanner.

#### Heating

Temperature increases produced in association with MRI have been studied using *ex vivo* techniques to evaluate various metallic implants, devices, and objects that have a variety of sizes, shapes, and metallic compositions or that are made from conducting materials (1, 2). In general, reports have indicated that only minor temperature changes occur in association with MRI and relatively small metallic objects that are “passive” implants (i.e., those that are not electronically-activated), including items such as aneurysm clips, hemostatic clips, prosthetic heart valves, vascular access ports, and similar devices. Therefore, heat generated during MRI involving a patient with a small, passive implant does not appear to be a substantial hazard. Importantly, to date, there has been no report of a patient being seriously injured as a result of excessive heat that developed in a small passive implant or device.

However, MRI-related heating is potentially problematic for implants that have an elongated shape or those that form a conducting loop of a certain diameter. For example, substantial heating can occur under some MRI conditions for objects such as elongated implants (e.g., leads, wires, etc.) that form resonant antennas or that form resonant conducting loops.

The evaluation of heating for an implant or device is particularly challenging because of the many factors that effect temperature increases in these items. Variables that impact heating include, the following: the specific type of implant or device; the electrical characteristics of the implant or device; the radiofrequency (RF) wavelength of the MR system; the type of transmit RF coil that is used (i.e., transmit head versus transmit body RF coil); the amount of RF energy delivered (i.e., the specific absorption rate, SAR); the technique used to calculate or estimate SAR that is utilized by the MR system; the landmark position or body part undergoing MRI relative to the transmit RF coil; and the orientation or configuration of the implant or device relative to the source of RF energy (i.e., the transmit RF coil).

One aspect of MRI-related heating for an implant or device that may not be intuitive is that for a given item, heating can be substantially different depending on the frequency of RF that is applied. For example, evidence from an *ex vivo* study conducted by Shellock, et al. (33) reported that significantly *less* MRI-related heating occurred at 3-Tesla/128-MHz (whole-body-averaged SAR, 3-W/kg) versus 1.5-Tesla/64-MHz (whole-body-averaged SAR, 1.4-W/kg) for a pacemaker lead that was not connected to a pulse generator (same lead length, positioning, etc.). This phenomenon whereby less heating was observed at 128-MHz versus 64-MHz has also been observed for external fixation devices, Foley catheters with temperature sensors, neurostimulation systems, relatively long peripheral vascular stents, and other implants and devices. Therefore, it is vital to perform *ex vivo* testing to properly characterize MRI-related heating to identify potentially hazardous objects prior to subjecting patients with the respective items to MRI.

### Induced Currents

The potential for MRI procedures to injure patients by inducing electrical currents in implants or devices made from conductive materials such as cardiac pacemakers, neurostimulation systems, cochlear implants, and other similar items has been previously reported. The performance of *ex vivo* testing of implants and devices to assess induced currents is necessary mostly for electronically-activated devices. Recommendations have been presented to protect patients from injuries related to induced currents that may develop during MRI (1, 2).

### Artifacts

The type and extent of artifacts caused by the presence of metallic implants and devices have been described and tend to be easily recognized on MR images (5, 8, 11, 18-29). Signal loss and/or image distortion associated with metallic objects are predominantly caused by a disruption of the local magnetic field that perturbs the relationship between position and frequency. In some cases, there may be areas of high signal intensity seen along the edge of a signal void or when there is an abrupt change in the shape of the item (e.g., the tip of a biopsy needle). Additionally, artifacts may be caused by gradient switching due to the generation of eddy currents.

The extent of the artifact seen on an MR image is dependent on the object's magnetic susceptibility, size, shape, position in the patient's body, the technique used for imaging (i.e., the specific pulse sequence parameters), and the image processing method. Careful selection of pulse sequence parameters can decrease the size of artifacts and this is done routinely, especially for patients that undergo MRI with implants that have large metallic masses, such as hip or knee prostheses. Additionally, several new imaging or post-processing techniques have been described that substantially reduce artifacts associated with metallic objects.

## TERMINOLOGY FOR IMPLANTS AND DEVICES

With the growing use of MRI in the 1990s, the Food and Drug Administration (FDA) recognized the need for standardized tests to address MRI safety issues for implants and other medical devices (34-38). Thus, over the years, test methods have been developed by various organizations including the American Society for Testing and Materials (ASTM) International, with an ongoing commitment to ensure patient safety in the MRI environment (36-38).

The FDA is responsible for reviewing the MRI terminology and labeling that manufacturers provide for their devices. This terminology has evolved to keep pace with advances in MRI technology. Unfortunately, members of the MRI community frequently may not always understand the terms that are used and are often confused by the conditions that are specified in "MR Conditional" labeling. This lack of understanding may result in patients with implants being exposed to potentially hazardous MRI conditions or in inappropriately preventing them from undergoing needed examinations. Importantly, the current labeling terminology that exists is associated with expanded labeling information that relates to the conditions that are deemed acceptable to ensure patient safety.

## 380 MRI Issues for Implants and Devices

Prior to implementing the current terminology, the terms “MR Safe” and “MR Compatible” were used for labeling purposes. In time, it became apparent that these terms were somewhat confusing and often used interchangeably or incorrectly. In particular, these terms were frequently used without including the conditions for which the device had been demonstrated to be safe. Therefore, in an effort to develop more appropriate terminology and, more importantly, because the misuse of the terms could result in serious accidents for patients and others in the MRI environment, a new set of MRI labeling terms was developed and released in 2005 (35). Thus, this terminology, which is currently recognized by the FDA and applied to implants and devices is, as follows: (a) *MR Safe* - an item that poses no known hazards in all MRI environments. Using the terminology, MR Safe items are non-conducting, non-metallic, and non-magnetic items such as a plastic Petri dish. (b) *MR Conditional* - an item that has been demonstrated to pose no known hazards in a specified MRI environment with specified conditions of use. Conditions that define the MRI environment may include the strength of the static magnetic field value, the spatial gradient magnetic field value, the time-varying magnetic field value, the RF field value, and the specific absorption rate (SAR) level. Additional conditions, including the specific configuration for the item (e.g., the routing of leads used for a neurostimulation system) may be required. Other possible safety issues that may be part of the MR Conditional labeling include but are not limited to thermal injury, induced currents/voltages, electromagnetic interference, neurostimulation, acoustic noise, interaction among devices, the safe functioning of the item, and the safe operation of the MR system. (c) *MR Unsafe* - an item that is known to pose hazards in all MRI environments. MR Unsafe items include ferromagnetic items such as a pair of metallic scissors.

Because of the variety of MR systems (e.g., ranging from 0.2- to 9.4-Tesla) and conditions in clinical use today, the current terminology is intended to help elucidate labeling matters for medical devices and other items that may be used in the MRI environment to ensure the safe use of MRI technology. However, it should be noted that this updated terminology has not been applied retrospectively to the many implants and devices that previously received FDA approved labeling using the terms MR Safe or MR Compatible (in general, this applies to those objects tested prior to the release of the ASTM International information for labeling in 2005). Therefore, this important point must be understood to avoid undue confusion regarding the matter of the labeling that has been applied to previously tested implants (i.e., those labeled as MR Safe or MR Compatible) versus those that have recently undergone MRI testing (i.e., now labeled MR Safe, MR Conditional)(1, 2). Notably, the specific content of the MRI labeling for an implant or device may take various forms (especially for electronically-activated implants) as the format continues to be refined by the FDA in an ongoing effort to properly communicate this information to MRI health-care professionals.

## MRI INFORMATION FOR IMPLANTS AND DEVICES

New implants and devices are developed on an on-going basis which, as previously indicated, necessitates continuous endeavors to obtain current documentation for these items prior to subjecting patients to MRI. Importantly, the labeling that ensures the safe use of MRI is highly specific to the conditions that were utilized to assess the implant or device

## MRI Bioeffects, Safety, and Patient Management 381

and any deviation from the defined procedures can lead to deleterious effects, severe patient injuries, or fatalities, especially when an electronically-activated implant is present in the patient (1, 2). A selection of items evaluated for MRI issues is presented below in order to illustrate information for commonly encountered or unusual medical products (1, 2).

### ActiPatch

The ActiPatch (BioElectronics, Frederick, MD) is a medical, drug-free device that delivers pulsed electromagnetic frequency therapies to accelerate healing of soft tissue injuries. The ActiPatch has an embedded, battery-operated microchip that delivers continuous pulsed therapy to reduce pain and swelling. With regard to MRI, the ActiPatch must be removed prior to performing an MRI procedure to prevent possible damage to this device and the potential risk of excessive heating.

### ActiFlo Indwelling Bowel Catheter System

The ActiFlo Indwelling Bowel Catheter System (also known as the Zassi Bowel Management System, Hollister, Libertyville, IL) is intended for diversion of fecal matter to minimize external contact with the patient's skin, to facilitate the collection of fecal matter for patients requiring stool management, to provide access for colonic irrigation, and to administer medications or an enema. This system consists of a catheter, the collection bag, and the irrigation bag. The ActiFlo Indwelling Bowel Catheter System allows stool to drain directly from the rectum into a closed or drainable collection bag.

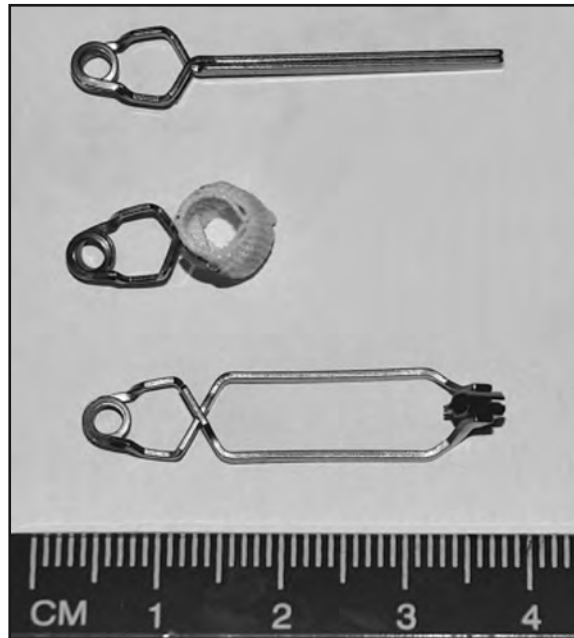
With regard to MRI issues, the ActiFlo Indwelling Bowel Catheter System was determined to be MR Conditional. Non-clinical testing demonstrated that this product is MR Conditional according to the following conditions: static magnetic field of 3-Tesla or less and highest spatial gradient magnetic field of 720-Gauss/cm or less. Important note: A metallic spring used for this device is located outside of the patient's body during the intended *in vivo* use of this product. Therefore, the only possible MRI-related issue pertains to magnetic field interactions. Heating and artifacts are of no concern. As such, the assessment of magnetic field interactions for this product specifically involved evaluations of translational attraction and torque in relation to exposure to a 3-Tesla MR system, only. Evaluations of MRI-related heating and artifacts were not conducted and are unnecessary.

### Aneurysm Clips

The surgical management of intracranial aneurysms and arteriovenous malformations (AVMs) by the application of aneurysm clips is a well-established procedure (**Figure 1**). The presence of an aneurysm clip in a patient referred for an MRI procedure represents a situation that requires the utmost consideration because of the associated risks. The following guidelines are recommended with regard to performing MRI in a patient or before allowing an individual with an aneurysm clip into the MRI environment: (a) Specific information (i.e., manufacturer, type or model, material, lot and serial numbers) about the aneurysm clip must be known, especially with respect to the material used to make the aneurysm clip, so that only patients or individuals with nonferromagnetic or weakly ferromagnetic clips are allowed into the MRI environment. The manufacturer provides this information in the labeling of the aneurysm clip. The implanting surgeon is responsible for

## 382 MRI Issues for Implants and Devices

**Figure 1.** Examples of aneurysm clips.



properly recording and communicating this information in the patient's or individual's records. (b) An aneurysm clip that is in its original package and made from Phynox, Elgiloy, MP35N, titanium alloy, commercially pure titanium or other material known to be nonferromagnetic or weakly ferromagnetic does not need to be evaluated for ferromagnetism. Aneurysm clips made from nonferromagnetic or "weakly" ferromagnetic materials in original packages do not require testing of ferromagnetism because the manufacturers ensure the pertinent MRI aspects of these clips and, therefore, are responsible for the accuracy of the labeling. (c) If the aneurysm clip is not in its original package and/or properly labeled, it should undergo testing for magnetic field interactions according to appropriate testing procedures to determine if it is safe. (d) The radiologist and implanting surgeon are responsible for evaluating the information pertaining to the aneurysm clip, verifying its accuracy, obtaining written documentation, and deciding to perform MRI after considering the risk versus benefit aspects for a given patient. (e) Consideration must be given to the static magnetic field strength that is to be used for the MRI procedure and the strength of the static magnetic field that was used to test magnetic field interactions for the aneurysm clip in question. Additional information for aneurysm clips may be found online at [www.MRIsafety.com](http://www.MRIsafety.com).

### Body Piercing Jewelry

Ritual or decorative body piercing is extremely popular as a form of self-expression. Different types of materials are used to make body piercing jewelry including ferromagnetic and nonferromagnetic metals, as well as non-metallic materials. The presence of body piercing jewelry that is made from ferromagnetic or conductive material of a certain shape may present a problem for a patient referred for an MRI procedure. Risks include uncomfortable



## MRI Bioeffects, Safety, and Patient Management 383

sensations from movement or displacement that may be mild-to-moderate depending on the site of the body piercing and the ferromagnetic qualities of the jewelry (e.g., size, degree of magnetic susceptibility, etc.). In extreme cases, serious injuries may occur. In addition, for body piercing jewelry made from conductive material, there is a possibility of MRI-related heating that could cause excessive temperature increases and burns.

Because of potential safety issues, metallic body piercing jewelry should be removed prior to entering the MRI environment. However, patients with body piercings are often reluctant to remove their jewelry. Therefore, if it is not possible to remove metallic body piercing jewelry, the patient or individual should be informed regarding the potential risks. In addition, if the body piercing jewelry is made from ferromagnetic material, some means of stabilization (e.g., application of adhesive tape or bandage) should be used to prevent movement or displacement.

To avoid potential heating of body piercing jewelry made from conductive materials, it is recommended to use gauze, tape, or other similar material to wrap the jewelry in such a manner as to insulate it (i.e., prevent contact) from the underlying skin. The patient should be instructed to immediately inform the MR system operator if any heating or other unusual sensation occurs in association with the body piercing jewelry.

According to Muensterer (39), even temporary or short-term piercing jewelry removal may lead to closure of the subcutaneous tract. Therefore, temporary replacement with a nonmetallic spacer may be indicated. Of course, this procedure must only be accomplished under the guidance and direction of a physician.

### Contraceptive Diaphragms

A contraceptive diaphragm may have a metallic ring that maintains it in position during its intended use. Thus, certain contraceptive diaphragms with metallic components may display positive magnetic field interactions in association with exposure to MR systems and, because of the metallic parts, substantial artifacts may be found. MRI examinations have been performed in patients with these devices without complaints or adverse sensations related to movement. Furthermore, there is no danger of heating of a contraceptive diaphragm during MRI under the conditions currently recommended by the United States Food and Drug Administration. Therefore, the presence of a diaphragm is not a contraindication for a patient undergoing an MRI examination using an MR system operating at 3-Tesla or less.

### Essure Device

The Essure Device (Bayer Healthcare) is a metallic implant developed for permanent female contraception. The presence of this implant is intended to alter the function and architecture of the fallopian tube, resulting in permanent contraception. The Essure Device is composed of 316L stainless steel, platinum, iridium, nickel-titanium alloy, silver solder, and polyethylene terephthalate fibers. The MRI assessment of this device involved testing for magnetic field interactions, heating, induced electrical currents, and artifacts using previously described techniques. The findings indicated that it is acceptable for a patient with the Essure Device to undergo MRI at 3-Tesla or less.

## 384 MRI Issues for Implants and Devices

### External Hearing Aids

External hearing aids are included in the category of electronically-activated devices that may be found in patients referred for MRI procedures. Exposure to the magnetic fields used for MRI can easily damage these devices. Therefore, a patient or other individual with an external hearing aid must not enter the MR system room. Fortunately, an external hearing aid can be readily identified and removed from the patient or individual to prevent damage associated with the MRI setting.

Other hearing devices may have external components as well as pieces that are surgically implanted. Hearing devices with external and internal components may be especially problematic for patients and individuals in relation to the use of MRI. Accordingly, patients and individuals with these particular hearing devices may not be allowed into the MRI environment because of the risk of damage to the components.

### Glaucoma Drainage Implants (Shunt Tubes)

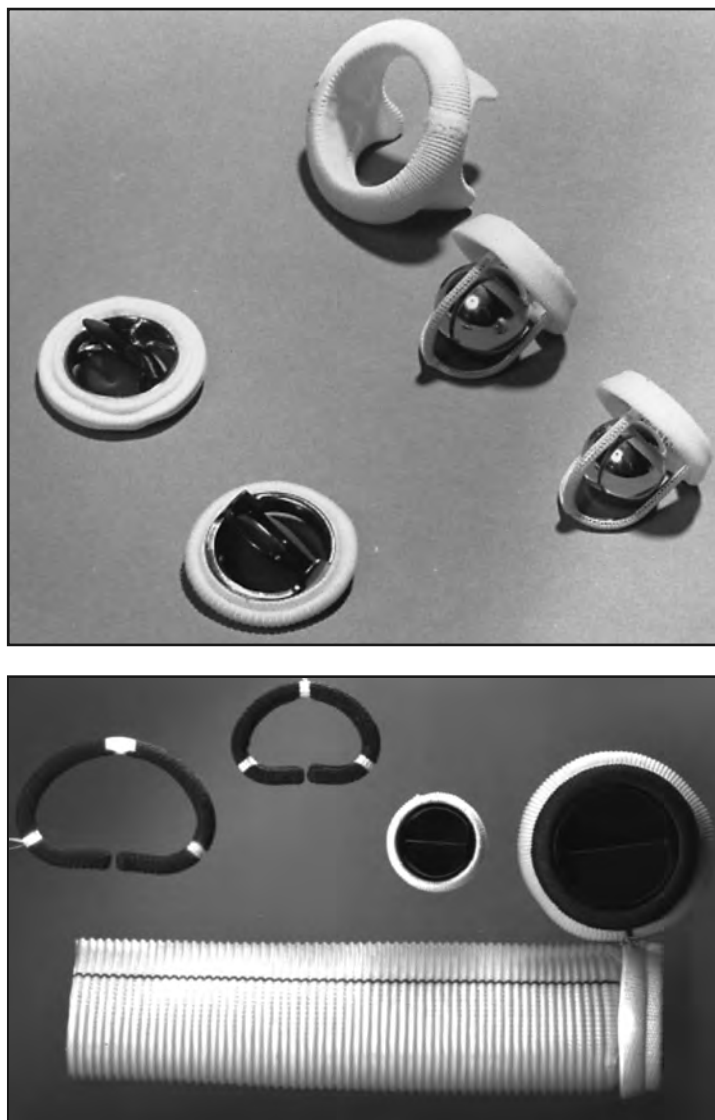
A glaucoma drainage implant or device, also known as a shunt tube, is implanted to maintain an artificial drainage pathway to control intraocular pressure for patients with glaucoma. Intraocular pressure is lowered when aqueous humor flows from inside the eye through the tube into the space between the plate that rests on the scleral surface and surrounding fibrous capsule. The implantation of a glaucoma drainage device is used to treat glaucoma that is refractory to medical and standard surgical therapy. For certain glaucoma drainage implants, radiographic findings may suggest the diagnosis of an orbital foreign body if the ophthalmic history is unknown, as reported by Ceballos and Parrish (40). In this case report, a patient was denied an MRI examination for fear of dislodging an apparent “metallic foreign body.” In fact, the patient had a Baerveldt glaucoma drainage implant, which was mistakenly identified as a metallic orbital object based on its radiographic characteristics (i.e., due to the presence of barium-impregnated silicone).

At least one glaucoma drainage implant, the ExPRESS Miniature Glaucoma Shunt (Optonol Ltd., Neve Ilan, Israel), is made from 316L stainless steel. However, many other glaucoma drainage implants are made from nonmetallic materials and are safe for patients undergoing MRI. Commonly used devices that do not contain metal and, as such, are MR Safe include, the following: (a) Baerveldt Glaucoma Drainage Implant (Pharmacia Co., Kalamazoo, MI) (b) Krupin-Denver Eye Valve to Disc Implant (E. Benson Hood Laboratories, Pembroke, MA) (c) Ahmed Glaucoma Valve (New World Medical, Rancho Cucamonga, CA) (d) Molteno Drainage Device (Molteno Ophthalmic Ltd., Dunedin, New Zealand), and (e) Joseph Valve (Valve Implants Limited, Hertford, England).

### Heart Valve Prostheses and Annuloplasty Rings

Many heart valve prostheses and annuloplasty rings have been evaluated for MRI issues, especially with regard to the presence of magnetic field interactions and heating associated with exposure to clinical MR systems operating at field strengths of as high as 3-Tesla (**Figure 2**). Of these, the majority displayed measurable yet relatively minor magnetic field interactions. That is, because the actual attractive forces exerted on the heart valve prostheses and annuloplasty rings were minimal compared to the force exerted by the beating heart

**Figure 2.** Examples of heart valve prostheses (a) and annuloplasty rings (b).



(i.e., approximately 7.2-N), an MRI procedure is not considered to be hazardous for a patient that has any heart valve prosthesis or annuloplasty ring tested relative to the field strength of the MR system used for the evaluation. Importantly, this recommendation includes the Starr-Edwards Model Pre-6000 heart valve prosthesis previously suggested to be a potential risk for a patient undergoing MRI. Heating has been reported to be relatively minor for heart valve prostheses and annuloplasty rings.

With respect to clinical MRI procedures, there has been no report of a patient incident or injury related to the presence of a heart valve prosthesis or annuloplasty ring. However,

## 386 MRI Issues for Implants and Devices

it should be noted that not all of these types of implants have been evaluated for MRI issues.

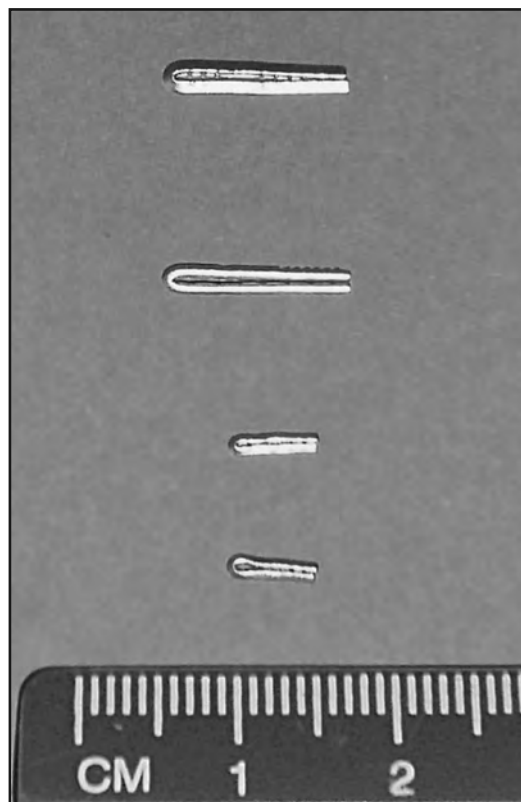
### Hemostatic (Ligating) Vascular Clips

In general, it was previously believed that because virtually all hemostatic (also called ligating) vascular clips and similar devices (including “endoclips” deployed through endoscopes) are made from nonferromagnetic materials such as tantalum, titanium, and certain forms of nonmagnetic stainless steel, patients with these implants are not at risk for injury in association with MRI (1, 2) (**Figure 3**). However, there are several hemostatic clips in use today that present potential problems for patients referred for MRI procedures. Patients with these clips require special attention to ensure the safe use of MRI. In some cases, MRI is deemed “unsafe”. For others, a “waiting” period is necessary and X-rays must be obtained and inspected to determine if the clips are present or not prior to performing MRI. Examples of MRI labeling statements for hemostatic clips that require further attention during the screening procedure are presented below.

#### *Long Clip, HX-600-090L*

The Long Clip HX-600-090L (Olympus Medical Systems Corporation) is indicated for placement within the gastrointestinal (GI) tract for the purpose of endoscopic marking, he-

**Figure 3.** Examples of hemostatic clips.



## MRI Bioeffects, Safety, and Patient Management 387

mostasis, or closure of GI tract luminal perforations within 20-mm as a supplementary method. For MRI, the Long Clip HX-600-090L labeling information is, as follows: Do not perform MRI procedures on patients who have clips placed within their gastrointestinal tracts. This could be harmful to the patient. Olympus endoscopic clips have been shown to remain in the patient an average of 9.4 days, but retention is based on a variety of factors and may result in a longer retention period. Prior to MRI, the physician should confirm there are no residual clips in the GI tract. The following techniques may be used for confirmation: (a) View the lesion under radiologic imaging. Olympus clip fixing devices are radiopaque. By using X-ray, the physician can determine if any residual clips are in the gastrointestinal tract. If no clips are evident under radiologic imaging, MRI may be accomplished. (b) Endoscopically examine the lesion. If no clips remain at the lesion, MRI may be accomplished.

### ***QuickClip2, HX-201LR-135 and HX-201UR-135***

The QuickClip2, HX-201LR-135 and HX-201UR-135 (Olympus Medical Systems Corporation) are indicated for placement within the gastrointestinal (GI) tract for the purpose of endoscopic marking, hemostasis, or closure of GI tract luminal perforations within 20-mm as a supplementary method. For MRI, the QuickClip2 (HX-201LR-135 and HX-201UR-135) labeling information is, as follows: Do not perform MRI procedures on patients who have clips placed within their gastrointestinal tracts. This could be harmful to the patient. Olympus endoscopic clips have been shown to remain in the patient an average of 9.4 days, but retention is based on a variety of factors and may result in a longer retention period. Prior to MRI, the physician should confirm there are no residual clips in the GI tract. The following techniques may be used for confirmation:

(a) View the lesion under radiologic imaging. Olympus clip fixing devices are radiopaque. By using X-ray, the physician can determine if any residual clips are in the gastrointestinal tract. If no clips are evident under radiologic imaging, MRI may be accomplished. (b) Endoscopically examine the lesion. If no clips remain at the lesion, MRI may be accomplished.

### **Pellets, Bullets, and Shrapnel**

The majority of pellets, bullets, and shrapnel tested for MRI issues were found to be composed of nonferromagnetic materials. However, these items are often “contaminated” by ferromagnetic metals. Ammunition that proved to be ferromagnetic tended to be manufactured in foreign countries and/or used for military applications. Shrapnel typically contains steel and, therefore, presents a potential hazard for patients undergoing MRI.

Because pellets, bullets, and shrapnel are frequently contaminated with ferromagnetic materials, the risk versus benefit of performing an MRI procedure should be carefully considered. Additional consideration must be given to whether the metallic object is located near or in a vital anatomic structure, with the assumption that the object is likely to be ferromagnetic and can potentially move.

Smugar, et al. (41) conducted an investigation to determine whether neurological problems developed in paralyzed patients with intraspinal bullets or bullet fragments in associ-

### 388 MRI Issues for Implants and Devices

ation with MRI performed at 1.5-Tesla. Patients were queried during scanning for symptoms of discomfort, pain, or changes in neurological status. Additionally, detailed neurological examinations were performed prior to MRI, post MRI, and at the patient's discharge. Based on these findings, Smugar, et al. (41) concluded that patients with complete spinal cord injury may undergo MRI if they have intraspinal bullets or fragments without concern for affects on their physical or neurological status. Thus, metallic fragments in the spinal canals of paralyzed patients are believed to represent only a relative contraindication to MRI.


Eshed, et al. (42) conducted a retrospective investigation of the potential hazards of patients undergoing MRI at 1.5-Tesla with retained metal fragments from combat and terrorist attacks. Metal fragments in 17 patients ranged in size between one and 10-mm. One patient reported a superficial migration of a 10-mm fragment after MRI. No other adverse reaction was reported. The authors concluded that 1.5-Tesla MRI examinations are safe in patients with retained metal fragments from combat and terrorist attacks that were not located in the vicinity of vital organs. However, caution is advised as well as an assessment of risk versus benefit for the patient.

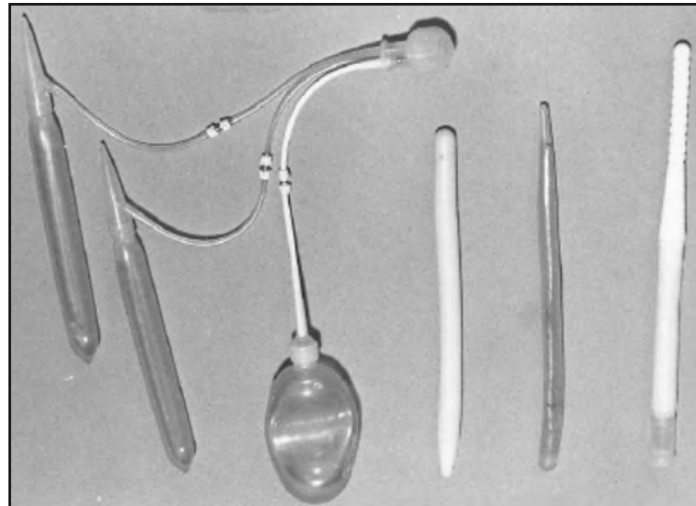
Dedini, et al. (30) studied bullets and shotgun pellets that were a representative sample of ballistic objects commonly encountered in association with criminal trauma using 1.5-, 3- and 7-Tesla MR systems (**Figure 4**). Findings indicated that non-steel containing bullets and pellets did not exhibit magnetic field interactions and that both steel-containing and non-steel-containing bullets did not significantly heat, even under extreme MRI conditions at 3-Tesla/128-MHz. Furthermore, steel-containing bullets were potentially unsafe for patients referred for MRI due to high magnetic field interactions, although this recommendation must be interpreted on a case-by-case basis with respect to the restraining effect of the specific tissue involved, time in place *in situ*, proximity to vital or delicate structures, and with careful consideration given to the risk versus benefit for the patient.

#### Penile Implants

Several types of penile implants have been evaluated for MRI issues. Of these, two (i.e., the Duraphase and Omniphase models) demonstrated substantial ferromagnetic qualities when exposed to a 1.5-Tesla MR system (1, 2) (**Figure 5**). Fortunately, it is unlikely for a penile implant to severely injure a patient undergoing MRI because of the relatively minor degree of magnetic field interactions. This is especially true when one considers the manner in which such a device is utilized. Nevertheless, it would be uncomfortable for a

**Figure 4.** Examples of bullets.



**Figure 5.** Examples of penile implants.

patient with a ferromagnetic penile implant to undergo an MRI examination. For this reason, subjecting a patient with the Duraphase or Omniphase penile implant to an MRI procedure is inadvisable. Findings for other penile implants indicated that they either exhibited no magnetic field interactions or relatively minor or “weak” magnetic field interactions. Heating was not observed to be substantial for any of the penile implants tested to date.

#### **PillCam (M2A) Capsule Endoscopy Device**

The PillCam (M2A) Capsule Endoscopy Device (Given Imaging Inc., Norcross, GA) is an ingestible device for use in the gastrointestinal tract (**Figure 6**). Peristalsis moves the PillCam (M2A) Capsule smoothly and painlessly throughout the gastrointestinal tract, transmitting color video images as it passes. The procedure allows the patient to continue daily activities during the endoscopic examination. The PillCam (M2A) Capsule Endoscopy Device has been utilized to diagnose diseases of the small intestine including Crohn’s Disease, celiac disease and other malabsorption disorders, benign and malignant tumors of the small intestine, vascular disorders, and medication related small bowel injuries.

Undergoing an MRI while the capsule is inside the patient’s body may result in serious damage to his/her intestinal tract or abdominal cavity. If the patient cannot positively verify the excretion of the PillCam (M2A) Capsule from his/her body, the patient should contact the physician for evaluation and possible abdominal X-ray before undergoing an MRI examination. Accordingly, the PillCam (M2A) Capsule is considered an MR Unsafe device.

#### **Vascular Access Ports**


Vascular access ports are implants commonly used to provide long-term vascular administration of chemotherapeutic agents, antibiotics, analgesics, and other medications. Vascular access ports are usually implanted in a subcutaneous pocket over the upper chest wall

### 390 MRI Issues for Implants and Devices

**Figure 6.** The PillCam (M2A) Capsule Endoscopy Device.



**Figure 7.** Examples of vascular access ports.





## MRI Bioeffects, Safety, and Patient Management 391

with the catheters inserted in the jugular, subclavian, or cephalic vein. These implants have a variety of similar features (e.g., a reservoir, central septum, and catheter) and may be constructed from different materials including stainless steel, titanium, silicone, and plastic (**Figure 7**). Because of the widespread use of vascular access ports catheters and the high probability that patients with these devices may require MRI procedures, it has been important to characterize the MRI issues for these implants.

Certain implantable vascular access ports evaluated for MRI issues showed measurable magnetic field interactions at 3-Tesla. However, the interactions were minor relative to the *in vivo* applications of these implants. For the vascular access ports tested to date, none have exhibited substantial heating during MRI at 1.5-Tesla/64-MHz or 3-Tesla/128-MHz. Therefore, an MRI procedure is acceptable when using an MR system operating at 3-Tesla or less in a patient that has one of the vascular access ports presented on [www.MRIsafety.com](http://www.MRIsafety.com).

With respect to MRI and artifacts, vascular access ports that will produce the least amount of artifact are made entirely from nonmetallic materials. The ones that produce the largest artifacts are composed of metal(s) or have metal in an unusual shape (e.g., the OmegaPort Access Port). Even vascular access ports made entirely from nonmetallic materials are, in fact, seen on MR images because they contain silicone (i.e., the septum portion of the port). Using MRI, the Larmor precessional frequency of fat is close to that of silicone (i.e., 100-Hz at 1.5-Tesla). Therefore, silicone used in the construction of a vascular access port may be observed on MR images with varying degrees of signal intensity depending on the pulse sequence that is used.

If a radiologist did not know that this type of vascular access port was present in a patient, the MR signal produced by the silicone component of the device could be considered an abnormality, or at the very least, present a confusing image. For example, this may cause a diagnostic problem in a patient evaluated for a rupture of a silicone breast implant, because silicone from the vascular access port may be misread as an extracapsular silicone implant rupture.

### MRI GUIDELINES FOR THE POST-OPERATIVE PATIENT

There is often confusion regarding the issue of performing MRI during the post-operative (post-op) period in a patient with a metallic implant or device. Studies have demonstrated that, if a metallic object is a “passive” implant or device (i.e., there is no electronically-activated or magnetically-activated component associated with the item) and it is made from nonferromagnetic material, the patient may undergo an MRI procedure immediately after implantation using an MR system operating at 1.5-Tesla or less (or, the static magnetic field strength that was used to test the device, including 3-Tesla)(1, 2). Notably, there are several reports that describe placement of vascular stents, coils, filters, and other implants using MRI-guided procedures that include the use of high field strength (1.5- and 3-Tesla) scanners (1, 2).

For a passive implant or device that exhibits “weakly magnetic” qualities, it may be necessary to wait a period of six weeks after implantation before performing an MRI procedure. For example, certain intravascular and intracavitary coils, stents, and filters desig-

## 392 MRI Issues for Implants and Devices

nated as weakly magnetic become firmly incorporated into tissue a minimum of six weeks following placement. In these cases, retentive or counterforces provided by tissue ingrowth, scarring, granulation or other mechanisms serve to prevent these objects from presenting risks or hazards to patients undergoing MRI. For patients with implants or devices that are weakly magnetic but rigidly fixed in the body (e.g., a hip prosthesis cemented in place; a heart valve implanted with sutures, etc.), they may be studied immediately after implantation. Specific information pertaining to the recommended post-op waiting period may be found in the labeling information or product insert for the implant or device.

If there is any concern regarding the integrity of the tissue with respect to its ability to retain the implant or object in place, the patient should not be exposed to MRI unless a radiologist gives careful consideration to the risk versus benefit aspects of the specific implant and the particular MRI conditions.

## CONCLUSIONS

This chapter provided an overview of MRI issues for implants and devices and presented MRI information for several categories of medical products. Notably, there are many additional implants and devices that remain to be evaluated with regard to MRI. With the continued advances in MRI technology and the development of more sophisticated implants and devices, there is an increased potential for hazardous situations to occur in the MRI environment. Thus, all of these items require testing to determine possible risks when present in patients referred for MRI procedures.

To ensure safety for individual and patients, MRI healthcare professionals should follow the guideline whereby an MRI procedure should only be performed in a patient with a medical product that has been previously tested and demonstrated to be safe. For implants and devices with MR Conditional labeling, the specific information for a given medical product must be carefully followed to prevent patient injuries or other problems.

## REFERENCES

1. Shellock FG. Reference Manual for Magnetic Resonance Safety: 2013 Edition. Los Angeles: Biomedical Research Publishing Group; 2013.
2. [www.MRIsafety.com](http://www.MRIsafety.com); Website devoted to MRI safety. Created and maintained by Frank G. Shellock, Ph.D.
3. Shellock FG, Crues JV. MR procedures: biologic effects, safety, and patient care. *Radiology* 2004;232:635-652.
4. Shellock FG, Spinazzi A. MRI safety update 2008: Part 2, screening patients for MRI. *AJR Am J Roentgenol* 2008;191:1140-9.
5. New PFJ, Rosen BR, Brady TJ, et al. Potential hazards and artifacts of ferromagnetic and nonferromagnetic surgical and dental materials and devices in nuclear magnetic resonance imaging. *Radiology* 1983;147:139-148.
6. Shellock FG, Crues JV. High-field MR imaging of metallic biomedical implants: An ex vivo evaluation of deflection forces. *AJR Am J Roentgenol* 1988;151:389-392.
7. Shellock FG. MR imaging of metallic implants and materials: A compilation of the literature. *AJR Am J Roentgenol* 1988;151: 811-814.

## MRI Bioeffects, Safety, and Patient Management 393

8. Shellock FG, Schatz CJ. High field strength MRI and otologic implants. *AJNR Am J Neuroradiol* 1991;12:279-281.
9. Kanal E, Shellock FG. MR imaging of patients with intracranial aneurysm clips. *Radiology* 1993;187:612-614.
10. Shellock FG, Morisoli S, Kanal E. MR procedures and biomedical implants, materials, and devices: Update 1993. *Radiology* 1993;189:587-599.
11. Nogueira M, Shellock FG. Otologic bioimplants: Ex vivo assessment of ferromagnetism and artifacts at 1.5 Tesla. *AJR Am J Roentgenol* 1995;163:1472-1473.
12. Kanal E, Shellock FG. Aneurysm clips: effects of long-term and multiple exposures to a 1.5 Tesla MR system. *Radiology* 1999;210:563-5659.
13. Kangarlu A, Shellock FG. Aneurysm clips: evaluation of magnetic field interactions with an 8.0-T MR system. *J Magn Reson Imaging* 2000;12:107-111.
14. Shellock FG. MR safety update 2002: Implants and devices. *J Magn Reson Imaging* 2002;16:485-496, 2002.
15. Shellock FG. Biomedical implants and devices: assessment of magnetic field interactions with a 3.0-Tesla MR system. *J Magn Reson Imaging* 2002;16:721-732
16. Shellock FG, Tkach JA, Ruggieri PM, et al. Aneurysm clips: evaluation of magnetic field interactions using "long-bore" and "short-bore" 3.0-Tesla MR systems. *AJNR Am J Neuroradiol* 2003;24:463-471.
17. Baker KB, Tkach JA, Nyenhuis JA, et al. Evaluation of specific absorption rate as a dosimeter of MRI-related implant heating. *J Magn Reson Imaging* 2004;20:315-320.
18. Shellock FG, Forder JR. Drug eluting coronary stent: in vitro evaluation of magnetic resonance safety at 3 Tesla. *J Cardiovasc Magn Reson* 2005;7:415-9.
19. Shellock FG, Habibi R, Knebel J. Programmable CSF shunt valve: in vitro assessment of MR imaging safety at 3T. *AJNR Am J Neuroradiol* 2006;27:661-5.
20. Shellock FG, Wilson SF, Mauge CP. Magnetically programmable shunt valve: MRI at 3-Tesla. *Magn Reson Imaging* 2007;25:1116-21.
21. Shellock FG, Valencerina S. In vitro evaluation of MR imaging issues at 3T for aneurysm clips made from MP35N: Findings and information applied to 155 additional aneurysm clips. *AJNR Am J Neuroradiol* 2010;31:615-9.
22. Shellock FG, Bedwinek A, Oliver-Allen M, Wilson SF. Assessment of MRI issues for a 3-T "immune" programmable CSF shunt valve. *AJR Am J Roentgenol* 2011;197:202-7.
23. Gill A, Shellock FG. Assessment of MRI issues at 3-Tesla for metallic surgical implants: findings applied to 61 additional skin closure staples and vessel ligation clips. *J Cardiovasc Magn Reson* 2012;14:1-7.
24. Karacozoff AM, Shellock FG, Wakhloo AK. A next-generation, flow-diverting implant used to treat brain aneurysms: in vitro evaluation of magnetic field interactions, heating and artifacts at 3-T. *Magn Reson Imaging* 2013;31:145-9.
25. Escher KB, Shellock FG. An in vitro assessment of MRI issues at 3-Tesla for antimicrobial, silver-containing wound dressings. *Ostomy Wound Manage* 2012;58:22-7.
26. Shellock FG, Meepos LN, Stapleton MR, Valencerina S. In vitro magnetic resonance imaging evaluation of ossicular implants at 3 T. *Otol Neurotol* 2012;33:871-7.
27. Shellock FG, Knebel J, Prat AD. Evaluation of MRI issues for a new neurological implant, the Sensor Reservoir. *Magn Reson Imaging* 2013;31:1245-50.
28. Karacozoff AM, Shellock FG. In vitro assessment of a fiducial marker for lung lesions: MRI issues at 3 T. *AJR Am J Roentgenol* 2013;200:1234-7.
29. Sammet CL, Yang X, Wassenaar PA, et al. RF-related heating assessment of extracranial neurosurgical implants at 7 T. *Magn Reson Imaging* 2013;31:1029-34.

## 394 MRI Issues for Implants and Devices

30. Dedini RD, Karacozoff AM, Shellock FG, et al. MRI issues for ballistic objects: information obtained at 1.5-, 3- and 7-Tesla. *Spine J* 2013;13:815-22.
31. Liu Y, Chen J, Shellock FG, Kainz W. Computational and experimental studies of an orthopedic implant: MRI-related heating at 1.5-T/64-MHz and 3-T/128-MHz. *J Magn Reson Imaging* 2013;37:491-7.
32. Dula AN, Virostko J, Shellock FG. Assessment of MRI issues at 7-Tesla for twenty-eight implants and other objects. *AJR Am J Roentgenol* (In Press)
33. Shellock FG, Valencerina S, Fischer L. MRI-related heating of pacemaker at 1.5- and 3-Tesla: Evaluation with and without pulse generator attached to leads. *Circulation* 2005;112;Supplement II:561.
34. Woods TO. Standards for medical devices in MRI: present and future. *J Magn Reson Imaging* 2007;26:1186-1189.
35. Shellock FG, Woods TO, Crues JV. MR labeling information for implants and devices: explanation of terminology. *Radiology* 2009;253:26-30.
36. American Society for Testing and Materials International. F2052. Standard test method for measurement of magnetically induced displacement force on passive implants in the magnetic resonance environment. American Society for Testing and Materials International, West Conshohocken, PA.
37. American Society for Testing and Materials International. F2182. Test method for Measurement of radio frequency induced heating near passive implants during magnetic resonance imaging. American Society for Testing and Materials International, West Conshohocken, PA.
38. American Society for Testing and Materials International. F2119-07, Standard test method for evaluation of MR image artifacts from passive Implants. American Society for Testing and Materials International, West Conshohocken, PA.
39. Muensterer OJ. Temporary removal of navel piercing jewelry for surgery and imaging studies. *Pediatrics* 2004;114:e384-6.
40. Ceballos EM, Parrish RK. Plain film imaging of Baerveldt glaucoma drainage implants. *AJNR Am J Neuroradiol* 2002;23:935-937.
41. Smugar SS, Schweitzer ME, Hume E. MRI in patients with intraspinal bullets. *J Magn Reson Imaging* 1999;9:151-153.
42. Eshed I, Kushnir T, et al. Is magnetic resonance imaging safe for patients with retained metal fragments from combat and terrorist attacks? *Acta Radiol* 2010;51:170-4